

Quality of CT Images Acquired with Power Injection of an Arm Port

Hager Haggag¹, Christine Roh¹, Ian Chan¹, Brent
Burbridge², David Leswick²

¹University of Saskatchewan Medical Students

²University of Saskatchewan, Department of Medical Imaging

No conflicts of interest to declare

Learning Objectives

- Compare CT image quality with intravenous contrast injection via Angiodynamics arm ports versus conventional peripheral vein intravenous injection
- Offer guidance about whether to inject contrast via a port into the right atrium or to use a peripheral vein, when conducting a CT

Background

- The use of central venous catheters has increased dramatically over the past 40 years¹.
- These devices are essential for many clinical treatments including access for chemotherapy, antibiotics, and blood transfusions².
- Indwelling catheters terminating in a port are particularly useful for intermittent treatment for malignancies³.
- Advantages of ports include protection of the device from damage or infection by the overlying skin and a reduction in venipuncture injuries and infusion complications^{1,4,5}.

¹ Denny DF Jr. Placement and management of long-term central venous access catheters and ports. *AJR Am J Roentgenol* 1993;161:385–93.

² Schiffer CA, Mangu PB, Wade JC, Camp-Sorrell D, Cope DG, El-Rayes BF, et al. Central venous catheter care for the patient with cancer: American Society of Clinical Oncology clinical practice guideline. *J Clin Oncol* 2013;31:1357–70.

³ Kawamura J, Nagayama S, Nomura A, Itami A, Okabe H, Sato S, et al. Long-term outcomes of peripheral arm ports implanted in patients with colorectal cancer. *Int J Clin Oncol* 2008;13:349–54.

⁴ Walser EM. Venous access ports: indications, implantation technique, follow-up, and complications. *Cardiovasc Intervent Radiol* 2012;35:751–64.

⁵ Burbridge B, Stoneham G, Szkup P, Otani R, Kriegler S. Catheter fracture and embolization associated with arm implantation of the cook vital port. *Can Assoc Radiol J.* 2013;64:369–73.

Introduction



- In this study, we investigated the Angiodynamics Vortex Smart Port Mini (Angiodynamics Inc., Manchester, GA, USA).
- These ports were inserted into the upper arm with the tip of the attached catheter at the right atrial/superior vena cava (SVC) junction.
- This particular arm port model is approved for power injection of computed tomography (CT) contrast agent, which has traditionally not been possible with other arm ports.

Hypothesis

- CT image quality obtained via power port contrast injection is superior to images obtained via peripheral vein contrast injection.
 - Reasoning: central delivery of contrast bolus would maintain tighter bolus of contrast while reducing streak artifact from concentrated contrast in the brachiocephalic veins, superior vena cava and right heart

Methods

- We performed a retrospective cohort study of patients who had a power injectable arm port inserted between July 2013 and June 2014.
- Ethics approval for this study was obtained from our local biomedical research committee (University of Saskatchewan Research Ethics Board) and data review was in compliance with the Health Information Protection Act (HIPA).

Methods

- Subjects were identified by reviewing a database of patients with an Angiodynamics arm port who had undergone contrast-enhanced CT (n=54).
- The majority of CT exams (n=44) were 'mixed contrast phase' studies of the chest, abdomen and pelvis (contrast present within the systemic arterial and portal venous systems). To reduce variability from timing of contrast bolus, we only assessed these studies.
- Only patients with a previous similar scan with contrast injection via a peripheral arm vein were included in the study (n=18).
- Therefore, each subject served as their own control.

Methods

- CT images were reviewed on Philips iSite Radiology Picture Archive and Communication System (Koninklijke Philips Electronics, Netherlands).
- Scan dates ranged between July 2012 to July 2014, with CT slice thickness ranging from 3.8 to 5 mm, and volume CT dose index (CTDI_{vol}) ranging from 2.2 to 20.43 mGy.
- CT scans were from four acute care centres (Royal University Hospital, Saskatoon City Hospital, Cypress Regional Hospital, and Battlefords Union Hospital).

Methods

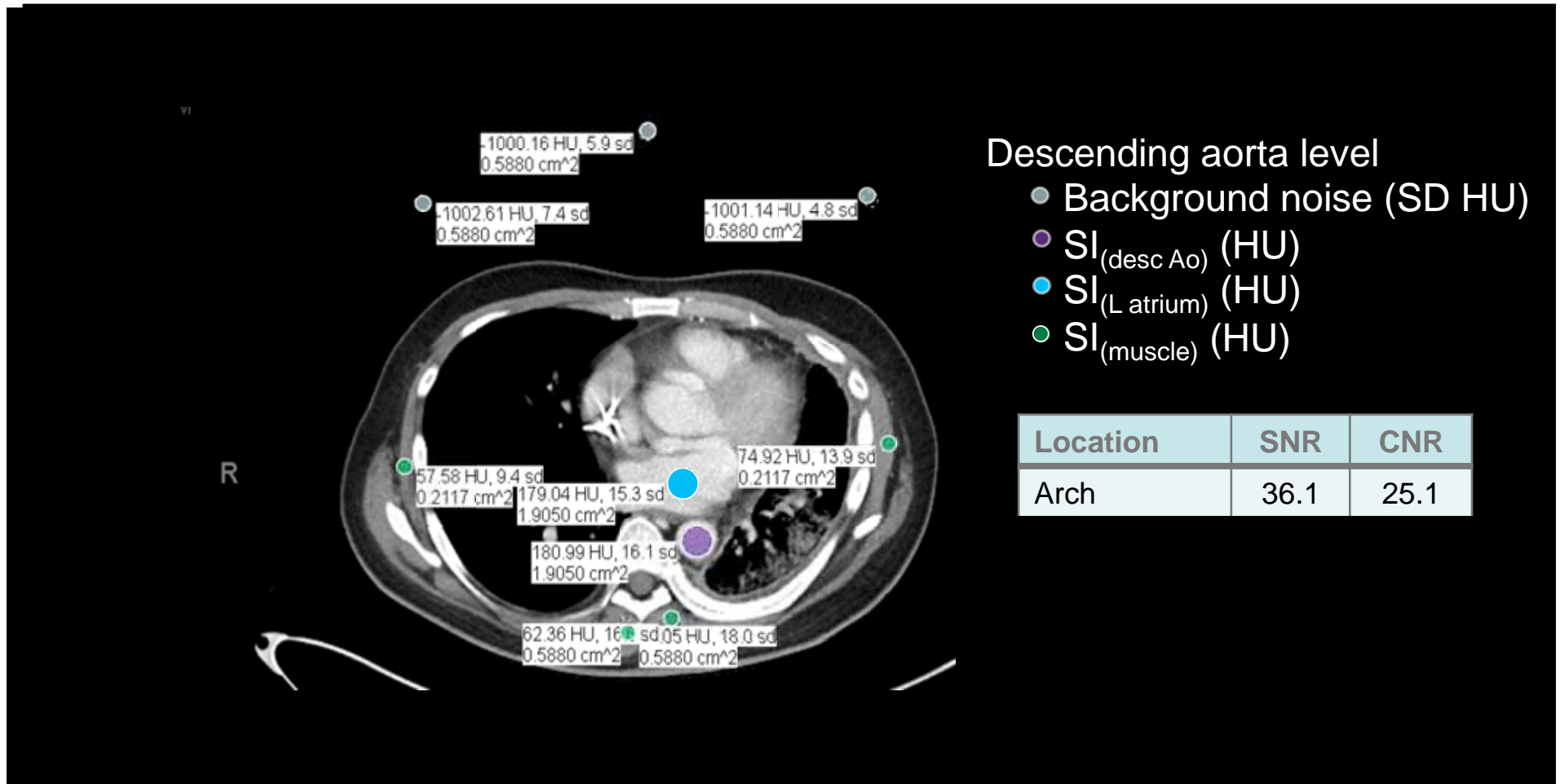
- Assessment of objective image quality was performed by measuring signal-to-noise (SNR) and contrast-to-noise (CNR) ratios, as described by Heyer et al¹.
- SNR and CNR were determined at three anatomical levels: (1) aortic arch, (2) main pulmonary artery and right pulmonary artery and (3) descending aorta and left atrium.
 - $SNR_{\text{structure}} = SI_{\text{structure}}/BN$
 - $CNR_{\text{structure}} = (SI_{\text{structure}} - SI_{\text{muscle}})/BN$
 - where $SI_{\text{structure}}$ is signal intensity (SI) of a structure, SI_{muscle} is mean SI of muscles, and BN is background noise

¹ Heyer CM, Mohr PS, Lemburg SP, Peters SA, Nicolas V. Image quality and radiation exposure at pulmonary CT angiography with 100- or 120-kVp protocol: prospective randomized study. Radiology 2007;245:577–83.

Methods – SNR and CNR

- SI values were calculated by measuring regions of interest (ROI), which were positioned to include adequate cross-sectional area of structures and avoid noise such as fat and bone.
- Muscle groups used to measure SI included the right and left pectoralis major, infraspinatus and serratus anterior muscles.
- A standard deviation of three ROIs in the surrounding air was used to determine background noise.

Example case.



Patient with injection via left port line with tip right atrium

Statistical analysis

- Data analysis was performed using two-tailed t-tests in Microsoft Excel for Mac 2011 version 14.4.4 (Microsoft Corporation, Redmond, WA, USA).

Results

- There were 18 subjects in our study
 - 9 male, 9 female
 - mean age 57.3 years [range, 26-84 years]
 - 2 scans each (port and peripheral iv injection)

Results

Tabular comparison of SNR & CNR at each site

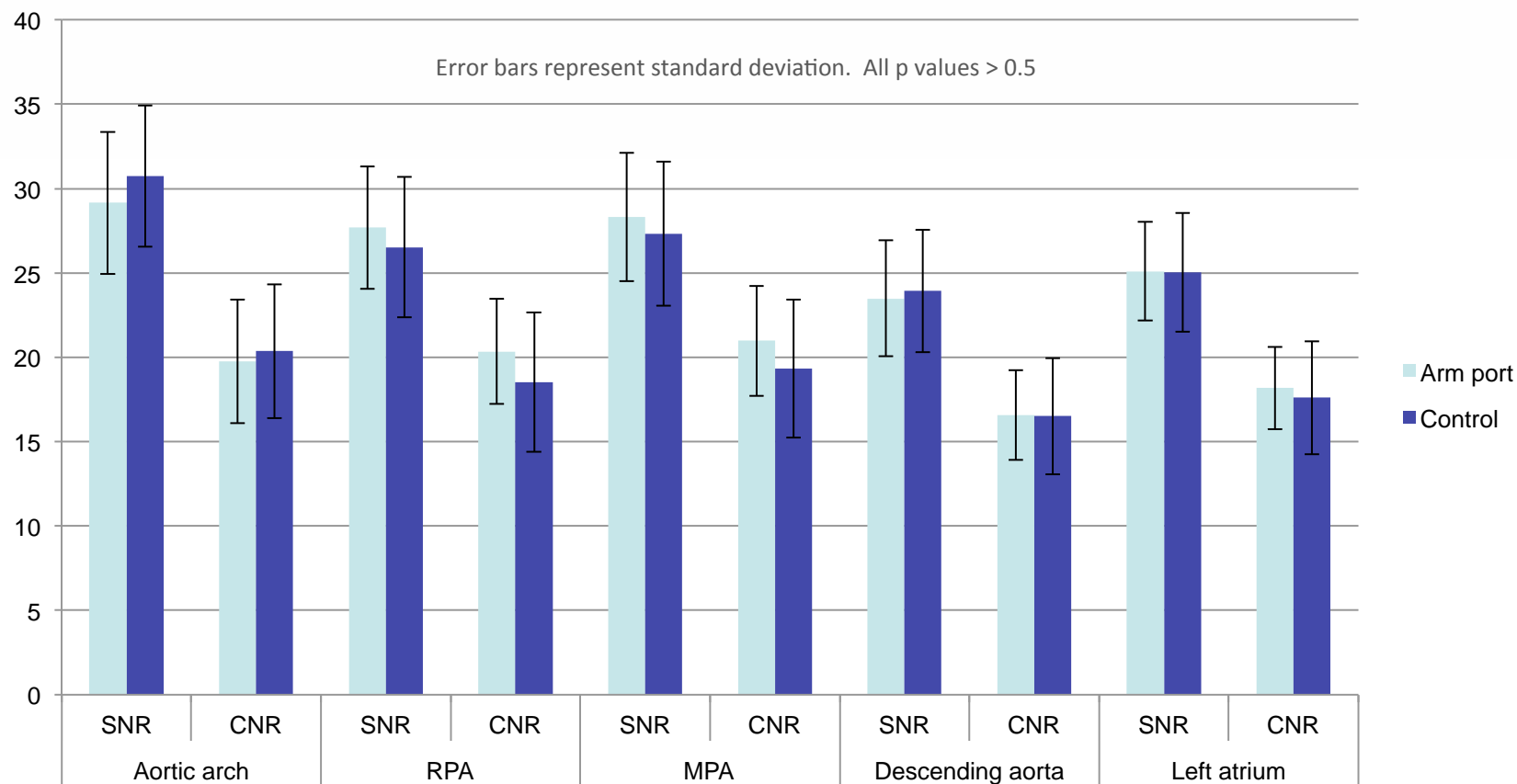
	Aortic arch		RPA		MPA		Descending aorta		Left atrium	
	Arm port	Control	Arm port	Control	Arm port	Control	Arm port	Control	Arm port	Control
SNR	29.2 ± 8.4	30.7 ± 8.4	27.7 ± 7.3	26.5 ± 8.3	28.3 ± 7.6	27.3 ± 8.5	23.5 ± 6.9	23.9 ± 7.3	25.1 ± 5.8	25.0 ± 7.1
CNR	19.8 ± 7.3	20.4 ± 7.9	20.4 ± 6.3	18.5 ± 8.3	21.0 ± 6.5	19.3 ± 8.2	16.6 ± 5.3	16.5 ± 6.9	18.2 ± 4.9	17.6 ± 6.7
T-test	SRN: p=0.58 CRN: p=0.82		SRN: p=0.66 CRN: p=0.47		SRN: p=0.72 CRN: p=0.51		SRN: p=0.85 CRN: p=0.97		SRN: p=0.99 CRN: p=0.78	

All SNR and CNR data presented as average ± standard deviation

- SNR & CNR similar for both injection techniques at all locations
- No significant difference at any location (all p values >0.5)

Results

Graphical comparison of SNR & CNR at each site



- SNR & CNR similar for both injection techniques at all sites
- No significant difference at any location (all p values >0.5)

Discussion

- There were no statistically significant differences in objective image quality.
- We had expected improved homogeneity of contrast opacification of the vessels with port injection because:
 - More compact bolus of contrast with less mixing/swirling with unopacified blood
 - Less noise from streak artifact from heavily concentrated contrast in the SVC and brachiocephalic veins during peripheral venous injection
- These potential benefits were out weighed by mixing of contrast during the phase assessed on these CT scans.
- However, this is the most common type of scan for these patients to receive

Conclusion

- There was no statistically significant difference in objective CT image quality for mixed phase contrast enhancement when contrast injection via peripheral vein was compared to power injection of an arm port.
- Power injection of a central venous catheter attached to an arm port is a safe and acceptable alternative strategy for contrast-enhanced CT^{1,2}.
- Our work demonstrates that contrast injection via port has equivalent image quality when compared to conventional peripheral intravenous injection technique.

¹ Herts B, O'Malley C, Wirth S, Lieber M, Pohlman B. Power injection of contrast media using central venous catheters: feasibility, safety, and efficacy. *AJR Am J Roentgenol.* 2001;176:447–453.

² Plumb AAO, Murphy G. The use of central venous catheters for intravenous contrast injection for CT examinations. *Br J Radiol.* 2011;84(999):197–203.

Limitations

- This was a retrospective study and therefore we were not able to control for parameters such as CT scanner site, CT scanner design, protocols, and injection rates.
- There may have been variability in these parameters as we reviewed scans from four different acute care centers. Although this is a limitation, it also reflects real-world use of the port lines for injections in multiple centers.
- We performed comparison of CT images in the mixed phase of intravenous contrast enhancement.
- We suspect that the SNR and overall image quality would be better for the port group if the same comparison was performed for CT pulmonary embolism (PE) studies. We plan on exploring the possibility of superior image quality on CT PE studies in the future.

Acknowledgements

- Thank you for spending the time to read our presentation.
- We gratefully acknowledge:
 - University of Saskatchewan College of Medicine and Department of Medical Imaging for guidance and supporting conference presentation costs.
 - The CAR for giving us the opportunity to present at the 2015 Joint Congress on Medical imaging and Radiation Sciences
- Contact information:
 - Hager Haggag: h.haggag@usask.ca
 - Christine Roh: christine.roh@usask.ca
 - Ian Chan: i.chan@usask.ca
 - Brent Burbridge: brent.burbridge@usask.ca
 - David Leswick: david.leswick@saskatoonhealthregion.ca